




Contents lists available at ScienceDirect

International Journal for Parasitology: Parasites and Wildlife

journal homepage: www.elsevier.com/locate/ijppaw

Chewing lice *Trichodectes pinguis pinguis* in Scandinavian brown bears (*Ursus arctos*)



Núria Fandos Esteruelas^{a,*}, Jonas Malmsten^b, Caroline Bröjer^b, Giulio Grandi^c,
Anders Lindström^c, Paul Brown^d, Jon E. Swenson^{e,f}, Alina L. Evans^a, Jon M. Arnemo^{a,g}

^a Department of Forestry and Wildlife Management, Faculty of Applied Ecology and Agricultural Sciences, Hedmark University of Applied Sciences, Campus Evenstad, NO-2418 Elverum, Norway

^b Department of Pathology and Wildlife Diseases, National Veterinary Institute, SE-75189 Uppsala, Sweden

^c Department of Microbiology, National Veterinary Institute, SE-75189 Uppsala, Sweden

^d Department of Life Sciences, Natural History Museum, SW7 5BD London, UK

^e Department of Ecology and Natural Resource Management, Norwegian University of Life Sciences, PO Box 5003, NO-1432 Ås, Norway

^f Norwegian Institute for Nature Research, PO Box 5685 Sluppen, Trondheim NO-7485, Norway

^g Department of Wildlife, Fish and Environmental Studies, Swedish University of Agricultural Sciences, Skogsmarksgränd Street, SE-901 83 Umeå, Sweden

ARTICLE INFO

Article history:

Received 4 December 2015

Received in revised form

8 February 2016

Accepted 23 February 2016

Keywords:

Alopecia

Biting lice

Brown bear

Sweden

Trichodectes pinguis

Ursus arctos

ABSTRACT

In April 2014 and 2015, we noted localized alopecia (neck, forelimbs, and chest) and hyperpigmentation on two adult brown bears (*Ursus arctos*) captured in central-south Sweden for ecological studies under the Scandinavian Brown Bear Research Project. In spring 2015, a brown bear was shot because of human-wildlife conflict in the same region. This bear also had extensive alopecia and hyperpigmentation. Ectoparasites were collected from the affected skin areas in all three individuals and preserved in ethanol for identification. Based on morphological characteristics, the lice were identified as *Trichodectes* spp. and *Trichodectes pinguis pinguis*. To our knowledge, these are the first reported cases of chewing lice in free-ranging brown bears in Scandinavia.

© 2016 The Authors. Published by Elsevier Ltd on behalf of Australian Society for Parasitology. This is an open access article under the CC BY-NC-ND license (<http://creativecommons.org/licenses/by-nc-nd/4.0/>).

Chewing or biting lice are small (a few mm long), wingless, dorsoventrally flattened insects that parasitize birds and mammals. In mammals, they mainly feed on dead skin and skin products (Johnson and Clayton, 2003). They are permanent ectoparasites (their entire life cycle occurs on the host) and host-specific. The transmission is through direct physical contact between hosts, e.g. during mating, aggressive behavior or mother-offspring contact (Durden, 1983).

Trichodectes spp. (Nitzsch, 1818; Insecta, Phthiraptera, Ischnocera, Trichodectidae) is a genus of chewing lice containing 16 species that parasitize ungulates and carnivores worldwide, including ursids (Rékási, 1994; Durden, 2001). *Trichodectes pinguis*

is considered the chewing lice of bears. It can be distinguished from other *Trichodectes* spp. by, amongst other things, the trapezoid shape of its head. Two subspecies have been described in the literature: *T. pinguis pinguis* in brown bears (*Ursus arctos*), and *T. pinguis euarctidos* mainly found in American black bears (*Ursus americanus*) (review in Rogers and Rogers, 1976). They differ in subtle characters, one of the most easily spotted is the brownish pleural plates of *T. p. euarctidos* located close to the abdominal spiracles (Hopkins, 1954). In the most recent world checklist of lice by Price et al. (2003), *T. pinguis* and *Trichodectes euarctidos* have been referred to as species rather than subspecies.

On 25 April 2014, we captured a 5-year-old female brown bear, ID No. W1017, in Gävleborg County, in south-central Sweden (61.627265° N, 14.779787° E) for ecological studies under the Scandinavian Brown Bear Research Project (SBBRP). This bear weighed 75 kg and was in good body condition for her sex-age group (SBBRP 2015, unpublished data). During the physical examination, we discovered an area with complete alopecia in the ventral part of the neck and upper part of the chest (Fig. 1a, b). No

* Corresponding author.

E-mail addresses: nfanest@gmail.com (N.F. Esteruelas), jmalmsten@gmail.com (J. Malmsten), caroline.brojer@sva.se (C. Bröjer), giulio.grandi@sva.se (G. Grandi), anders.lindstrom@sva.se (A. Lindström), p.brown@nhm.ac.uk (P. Brown), jon.swenson@nmbu.no (J.E. Swenson), alina.evans@hihm.no (A.L. Evans), jon.arnemo@hihm.no (J.M. Arnemo).




Fig. 1. A 5-year-old female brown bear (*Ursus arctos*), ID No. W1017, captured in Sweden. a) and b) April 2014: Hair loss in the ventral region of the neck and upper chest probably caused by *Trichodectes* spp. c) April 2015: Hair loss and scar tissue in the neck; no lice were found.

other dermatological signs or abnormalities were observed. No treatment was administered. Through careful visual examination of the affected areas, we discovered several ectoparasites. We collected 20 of them and preserved them in 80% ethanol. We submitted the parasites to the [National Veterinary Institute](#) in Uppsala, Sweden for identification, which was made on the basis of morphological characteristics ([Hopkins, 1954](#); [Lyal, 1985](#)). The parasites were identified at the genus level as *Trichodectes* spp. The same bear was recaptured a year later, on 13 May 2015 (61.619168° N, 14.692434° E). It weighed 80 kg and was below the average body condition for her sex-age group. Hair had re-grown in the area of her upper chest. However, there was still an area of alopecia on her neck, and we noticed scarring of the skin along the sides of the neck ([Fig. 1c](#)). We were unable to find any lice. We attributed these more recent signs to the wearing of a GPS collar for the past year, and removed it from the bear.

On 17 April 2015, we captured a 15-year-old male brown bear, ID No. W1211, also in Gävleborg County (61.535394° N, 15.456055° E). The male weighed 157 kg and was in good body condition. However, it was partially alopecic on the shoulders, upper forelimbs, and chest, and completely alopecic on the left side of the thorax. In addition, the skin of the left thorax was hyperpigmented and lichenified, indicating chronic inflammation, pruritus, and scratching of the skin ([Fig. 2a](#)). We did not administer any treatment. Examination of the affected areas revealed the presence of several ectoparasites, of which we collected ($n = 10$) and preserved in 80% ethanol. We submitted the parasites to the Natural History Museum in London for identification. On the basis of morphological characteristics ([Lyal, 1985](#)), they were identified as *T. p. Pinguis*. The same bear was photographed on 22 June 2015 in a camera trap (Scout Guard model SG560V, located in 61.623395° N, 15.322697° E) when feeding on a moose (*Alces alces*) carcass. The alopecia was

still evident in the left upper forelimb and shoulder ([Fig. 2b](#)). In addition, we inspected hair collected from day beds nearby the location of the camera trap and found lice on them.

Captures were carried out according to an established protocol ([Arnemo et al., 2012](#)) and were approved by the Swedish Ethical Committee on Animal Research (application numbers C7/12 and C 18/15) and the Swedish Environmental Protection Agency.

In mid-May 2015, an adult male bear was shot just outside the village of Los in Gävleborg County (61.722175° N, 15.180187° E), because it had been determined to be a threat to public safety by the police. The carcass was transported to the [National Veterinary Institute](#) in Uppsala, Sweden, for post mortem examination. It was in average body condition, weighing 168 kg. The skin was completely alopecic in the area covering the chin, ventral part of the neck, axillary regions, and abdomen ([Fig. 3a, b](#)). In addition, moderate to severe dental and periodontal lesions were found, including periodontitis, gingivitis, feed impactions, incisal fractures, and suspected caries. Histologically, a moderate chronic eosinophilic to lymphocytic dermatitis was identified in affected areas. Moderate to high numbers of ectoparasites were found in the hair coat surrounding the areas with complete alopecia, and in the areas with partial alopecia. Ectoparasites were not found in the areas with healthy skin. The parasites were preserved in 70% ethanol. Species identification was performed using the same morphological keys (see above) at the Veterinary Institute in Uppsala, Sweden. The results showed that the bear was infested with *T. p. Pinguis* ([Fig. 4](#)). Other causes of alopecia and dermatitis were excluded by visual examination of skin and hair coat, and microscopic examination of skin scrapings and histological slides of skin.

The chewing lice of the European brown bear, *T. p. Pinguis*, was first discovered by Nitzsch in 1825, and his work was published by



Fig. 2. A 15-year-old male brown bear (*Ursus arctos*), ID No. W1211, parasitized by *Trichodectes pinguis pinguis*. Notice the areas with partial or complete hair loss, hyperpigmentation and lichenification of the skin. a) April 2015 at the time of capture. b) June 2015 when feeding on a carcass.

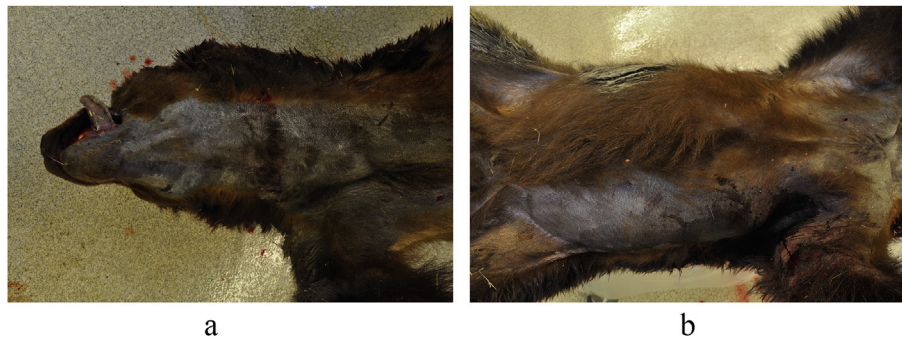

Fig. 3. Brown bear (*Ursus arctos*) killed because of human-wildlife conflict in south-central Sweden in May 2015. The bear showed extensive alopecia in the area covering a) the chin, ventral part of the neck; b) axillar region, and abdomen.



Fig. 4. Specimen of *Trichodectes pinguis pinguis* recovered from a brown bear (*Ursus arctos*) killed because of human-wildlife conflict in south-central Sweden in May 2015. The distance between the measuring bars is 1 mm.

Giebel in 1874. Despite this early description, there are very few published reports of the parasite in the literature. The next description of the louse was published by Burmeister in 1838 using Nitzsch's material. In 1948, Werneck described the female form of the parasite using samples from the British Museum that were

collected in Bosnia. We have not found any reports of chewing lice in brown bears in Scandinavia or in grizzly brown bears from North America. In fact, Thunberg (1798) reported that brown bears in Sweden were free of lice. *T. pinguis* has been reported with a prevalence of 0.7% in 135 brown bears from Hokkaido, Japan (Kadosaki et al., 1990). A different subspecies of chewing lice, *T. p. Euarctidos* (Hopkins, 1954), is commonly found in American black bears, where it has been reported in several states and provinces (Rogers, 1975; Rogers and Rogers, 1976; Worley et al., 1976; Addison et al., 1978; Manville, 1978; Yunker et al., 1980; Fowler and Miller, 2003; Nims and Durden, 2011). In the latest world checklist of lice, the subspecies were elevated to species rank (Price et al., 2003). *T. pinguis* has also been reported from Asiatic black bears (*Ursus thibetanus*). Nakagawa (1960) suggested a new subspecies, *T. p. Selenarctidos*, for the chewing lice of the Asiatic black bear, whereas other authors did not mention the subspecies of the parasite (Rogers and Rogers, 1976; Kadosaki et al., 1990; Yokohata et al., 1990). Chewing lice, *Tricholita ferrisi*, have also been documented in spectacled bears (*Tremarctos ornatus*), by Werneck in 1948. Price et al. (2003) classified the louse as *Werneckodectes ferrisi*.

Causes of alopecia and dermatitis in ursids are numerous. Bacterial infection (dermatophilosis, *Staphylococcus* sp., *Acinetobacter* sp.), parasites (mites, lice, nematodes), fungal infection (e.g. ringworm), hormonal disorders (e.g. hypothyroidism), allergy, nutritional causes (vitamin A deficiency), etc. have been documented to

produce dermatological symptoms in bear species in the literature (reviews in Fowler and Miller, 2003; Bourne and Vila-García, 2007).

Parasitic and fungal diseases are the main cause of skin lesions in bears (Fowler and Miller, 2003).

Ringworm (*Trichophyton* spp., *Microsporum canis*) has been seen in a number of bears, whereas other fungal diseases, including candidiasis and pythiosis, have been reported only rarely (Bourne et al., 2010). Among parasitic diseases, our differential diagnosis included *Demodex* spp., *Sarcoptes* spp., the audycoptid mite, *Ursicoptes americanus*, *Trichodectes* spp., and chiggers (larval stages of trombiculid mites *Eutrombicula splendens*) (Manville, 1978; Yunker et al., 1980; Schmitt et al., 1987; Forrester et al., 1993; Cunningham et al., 2001; Durden, 2001; Fowler and Miller, 2003; Dykstra et al., 2012). In addition, alopecia, fur matting, erythema, abrasions, edema, and ulceration have been reported in free-ranging wildlife as a result of wearing a radio-collar (Adams and Campbell, 1996; Hellgren et al., 1998; Gau et al., 2004; Krausman et al., 2004). Without the identification of lice, the lesions in the first bear, ID No. W1017, could be easily misinterpreted as being caused by the collar. Also, diseases of the oral cavity can have an effect on the immune system, and thus predispose to other infections (Pavlica et al., 2008), as might be the case in the human-wildlife conflict bear.

From 1984 through 2015, a total of 2047 captures of 748 individual bears have been carried out for scientific purposes in the SBBRP. Furthermore, brown bears are hunted legally in Sweden, and approximately 240 bears have been harvested annually in recent years (National Veterinary Institute, Sweden). Despite the high number of bears captured and handled, and harvested over the last few years in Scandinavia, only a few cases of bears with dermatological signs have been observed (Arnemo 2015, unpublished data). Lice were not reported in any of these cases. Although chewing lice are easy to detect through careful visual examination, bears have not routinely been inspected for lice or other ectoparasites. Except for heavy infestations or obvious clinical signs, lice could have gone undetected.

Wild mammals carry appreciable numbers of ectoparasites without serious consequences for their health (Butler and Roper, 1996; Durden, 2001). However, large infestations with detrimental effects to the host (e.g. anemia, dermatitis, alopecia, skin sensitization, decreased growth rates, secondary infections, transmission of parasites and pathogens, decrease of reproductive success, death) have been reported (Nelson et al., 1975, 1977; Schwartz et al., 1983; Mech et al., 1985; Foreyt et al., 1986; Durden, 2001). On the other hand, illness, nutritional deficiencies, host senility, immunosuppression, or inefficient grooming might lead to large infestations in mammals (Durden, 2001). In the cases described here, the clinical signs we observed (e.g. alopecia, dermatitis, pruritus) strongly suggest a negative effect on the bears. The impact of the louse infestation could be of relevance in case of alteration of blood parameters (e.g. inflammatory response) and/or behavioral modifications (e.g. restlessness, scratching, reduced feeding times). Also, hair loss may affect thermoregulation of the animal (e.g. lack of insulation and energy expenditure). This would be especially important in cases of extensive alopecia and during periods of high energy demands (e.g. reproduction) and hibernation.

To the best of our knowledge, this is the first report of *T. p. Pinguis* in free-ranging brown bears in Scandinavia.

Acknowledgments

We thank S. Brunberg and personnel of the SBBRP for their help with animal capture and handling. Y. Nemoto found lice on W1017 in 2014, and A.R. Græsli provided photos of that bear in 2015. A. Ordiz provided location and pictures from bear W1211 that was captured with a camera trap used for ongoing research of the

Scandinavian Wolf Research Project and the SBBRP in 2015. D. Roviani provided hair samples from day beds of the same bear. We also thank M. Cattet for useful comments on previous versions of the manuscript. The SBBRP is funded by the Swedish Environmental Protection Agency, the Norwegian Environmental Agency, the Swedish Association for Hunting and Wildlife Management, the Research Council of Norway, and the Austrian Science Fund. This is publication 206 of the SBBRP.

References

- Adams, I.T., Campbell, G.D., 1996. Improved radio-collaring for southern flying squirrels. *Wildl. Soc. Bull.* 24, 4–7.
- Addison, E., Pybus, M., Rietveld, H., 1978. Helminth and arthropod parasites of black bear, *Ursus americanus*, in central Ontario. *Can. J. Zool.* 56, 2122–2126.
- Arnemo, J.M., Evans, A.L., Fahlman, Å. (Eds.), 2012. Biomedical Protocols for Free-ranging Brown Bears, Gray Wolves, Wolverines and lynx. Hedmark University College, Evenstad, Norway. <http://www1.nina.no/RovviltPub/pdf/Biomedical%20Protocols%20Carnivores%20March%202012.pdf>. Accessed October 2015.
- Bourne, D.C., Vila-García, G. (Eds.), 2007. Bears: Health and Management. Wildpro, Wildlife Information Network, London. http://wildpro.twycrosszoo.org/List_Vols/Bears/Contents_bears.htm. Accessed January 2016.
- Bourne, D., Cracknell, J., Bacon, H., 2010. Veterinary issues related to bears (Ursidae). *Int. Zoo Yearb.* 44, 16–32.
- Burmeister, H., 1838. *Handbuch der Entomologie*, vol. 2. Enslin, Berlin, p. 435.
- Butler, J., Roper, T., 1996. Ectoparasites and sett use in European badgers. *Anim. Behav.* 52, 621–629.
- Cunningham, M.W., Phillips, L.A., Welbourn, C., 2001. Trombiculiasis in the florida black bear. *J. Wildl. Dis.* 37, 634–639.
- Durden, L.A., 1983. Sucking louse (*Hoplopleura erratica*: Insecta, Anoplura) exchange between individuals of a wild population of eastern chipmunks, *Tamias striatus*, in central Tennessee, USA. *J. Zool.* 201, 117–123.
- Durden, L.A., 2001. Lice (Phthiraptera). In: Samuel, W.M., Pybus, M.J., Kocan, A.A. (Eds.), *Parasitic Diseases of Wild Mammals*. Iowa State University Press, Ames, Iowa, pp. 3–17.
- Dykstra, J.A., Rogers, L.L., Mansfield, S.A., Wünschmann, A., 2012. Fatal disseminated blastomycosis in a free-ranging American black bear (*Ursus americanus*). *J. Vet. Diagn. Invest.* 24, 1125–1128.
- Foreyt, W., Rice, D., Kim, K., 1986. Pediculosis of mule deer and white-tailed deer fawns in captivity. *J. Am. Vet. Med. Assoc.* 189, 1172–1173.
- Forrester, D.J., Spalding, M.G., Wooding, J.B., 1993. Demodicosis in black bears (*Ursus americanus*) from Florida. *J. Wildl. Dis.* 29, 136–138.
- Fowler, M., Miller, A.H., 2003. Ursidae and hyaenidae. In: Fowler, M., Miller, A.H. (Eds.), *Zoo and Wild Animal Medicine*, fifth ed. Saunders, St. Louis, Missouri, pp. 523–534.
- Gau, R.J., Mulders, R., Ciarniello, L.M., Heard, D.C., Chetkiewicz, C.-L.B., Boyce, M., Gibeau, M.L., 2004. Uncontrolled field performance of Televit GPS-Simplex™ collars on grizzly bears in western and northern Canada. *Wildl. Soc. Bull.* 32, 693–701.
- Giebel, C.G., 1874. *Insecta epizoa. Die auf Säugethieren und Vögeln schmarotzenden Insecten nach Chr.* pp. 52–53. L. Nitzsch's Nachlass. Otto Wigand, Leipzig, Germany.
- Hellgren, E.C., Carney, D.W., Garner, N.P., Vaughan, M.R., 1988. Use of breakaway cotton spacers on radio collars. *Wildl. Soc. Bull.* 16, 216–218.
- Hopkins, C., 1954. Notes on some mallophaga from bears. *Entomol.* 87, 140–146.
- Johnson, K.P., Clayton, D.H., 2003. The biology, ecology, and evolution of chewing lice. In: Price, R.D., Hellenthal, R.A., Palma, R.L., Johnson, K.P., Clayton, D.H. (Eds.), *The Chewing Lice: World Checklist and Biological Overview*. Illinois Natural History Survey Special Publication, pp. 449–476.
- Kadosaki, M., Kawahara, A., Egusa, S., Hayashi, H., Wakana, S., 1990. Ectoparasites of the brown and black bears of Japan (I). *J. Jpn. Soc. Hares* 17, 59–78 (In Japanese with English summary).
- Krausman, P.R., Bleich, V.C., Cain III, J.W., Stephenson, T.R., DeYoung, D.W., McGrath, P.W., Jansen, B.D., 2004. Neck lesions in ungulates from collars incorporating satellite technology. *Wildl. Soc. Bull.* 32, 987–991.
- Lyal, C.H., 1985. A cladistic analysis and classification of trichodectid mammal lice (Phthiraptera, Ischnocera). *Bull. Br. Mus.* 51, 187–346.
- Manville, A.M., 1978. Ecto- and endoparasites of the black bear in northern Wisconsin. *J. Wildl. Dis.* 14, 97–101.
- Mech, L.D., Thiel, R.P., Fritts, S., Berg, W., 1985. Presence and effects of the dog louse *Trichodectes canis* (Mallophaga, Trichodectidae) on wolves and coyotes from Minnesota and Wisconsin. *Am. Midl. Nat.* 114, 404–405.
- Nakagawa, H., 1960. Notes on the mallophaga from the Asiatic black bear. *Jpn. Wildl. Bull.* 18, 217–222 (In Japanese with English summary).
- National Veterinary Institute, Sweden. <http://www.sva.se/en>. Accessed November 2015.
- Nelson, W., Keirans, J.E., Bell, J., Clifford, C., 1975. Host-ectoparasite relationships. *J. Med. Entomol.* 12, 143–166.
- Nelson, W., Bell, J., Clifford, C., Keirans, J., 1977. Review article: interaction of ectoparasites and their hosts. *J. Med. Entomol.* 13, 389–428.
- Nims, T.N., Durden, L.A., 2011. Ticks and lice of the black bear, *Ursus americanus*

- Pallas, in northern Georgia, USA, including a new state record for the chewing louse, *Trichodectes euarctidos* (Phthiraptera: Trichodectidae). *J. Entomol. Sci.* 46, 345–347.
- Pavlica, Z., Petelin, M., Junes, P., Erzen, D., Crossley, D.A., Skaleric, U., 2008. Periodontal disease burden and pathological changes in dogs. *J. Vet. Dent.* 25, 97–105.
- Price, R.D., Hellenthal, R.A., Palma, R.L., Johnson, K.P., Clayton, D.H., 2003. The chewing lice: world checklist and biological overview. *Ill. Nat. Hist. Surv. Spec. Publ.* 24, 501.
- Rékási, J., 1994. Chewing lice parasitizing mammals in Central Europe, with notes on louse taxonomy and biogeography. *Parasitol. Hung.* 27, 57–67.
- Rogers, L.L., 1975. Parasites of black bears of the lake superior region. *J. Wildl. Dis.* 11, 189–192.
- Rogers, L.L., Rogers, S.M., 1976. Parasites of bears: a review. *Intern. Conf. Bear. Res. Manage.* 3, 411–430.
- Schmitt, S.M., Cooley, T.M., Friedrich, P.D., Schillhorn van Veen, T.W., 1987. Clinical mange of the black bear (*Ursus americanus*) caused by *Sarcoptes scabiei* (Acarina, Sarcoptidae). *J. Wildl. Dis.* 23, 162–165.
- Schwartz, C.C., Stephenson, R., Wilson, N., 1983. *Trichodectes canis* on the Gray Wolf and Coyote on Kenai Peninsula, Alaska. *J. Wildl. Dis.* 19, 372–373.
- Thunberg, C.P., 1798. Beskrifning på svenske djur. In: Första classen, om Mammalia eller däggande djuren, pp. 20–24. J. F. Edman, Upsala, Sweden.
- Werneck, F.L., 1948. Os malófagos de mamíferos: Pte. I: *Amblycera* e *Ischnocera* (Phloptera e parte de hidectidae). *Rev. Bras. Biol.* 117–119.
- Worley, D.E., Fox, J.C., Winters, J.B., Jacobson, R.H., Greer, K.R., 1976. Helminth and arthropod parasites of grizzly and black bears in Montana and adjacent areas. *Int. Conf. Bear. Res. Manage.* 3, 411–430.
- Yokohata, Y., Fujita, O., Kamiya, M., Fujita, T., Kaneko, K., Ohbayashi, M., 1990. Parasites from the Asiatic black bear (*Ursus thibetanus*) on Kyushu Island. *Jpn. J. Wildl. Dis.* 26, 137–138.
- Yunker, C., Binninger, C., Keirans, J., Beecham, J., Schlegel, M., 1980. Clinical mange of the black bear, *Ursus americanus*, associated with *Ursicoptes americanus* (Acari: Audycoptidae). *J. Wildl. Dis.* 16, 347–356.